

# CERVICAL SARCOMA: A CASE REPORT

DJELTI Sihem

Department of Obstetrics and Gynecology

EHSU Nouar Fadela, Oran, Algeria



WORLD CONGRESS OF  
THE INTERNATIONAL  
FEDERATION FOR CANCER  
PREVENTION AND COLPOSCOPY



19<sup>TH</sup> CONGRESS OF  
**IFCPC**  
PARIS 2026

4 > 6 JUNE 2026

VERSAILLES - FRANCE  
PALAIS DES CONGRÈS



WORKING TO ELIMINATE  
LOWER GENITAL TRACT CANCERS

# Introduction & Objective

## Introduction

- Uterine sarcomas are rare (<5% of uterine cancers)
- Cervical sarcoma is extremely rare
- Diagnosis is challenging

## Objective

- To highlight diagnosis and management

# CASE REPORT

## Case Report

- 52-year-old woman
- Presented with abnormal bleeding
- Cervical tumor (FIGO stage I) (Figure 1)

## Treatment

- Hysterectomy + radiotherapy (Figure 2)

## Outcome

- No recurrence after 1 year

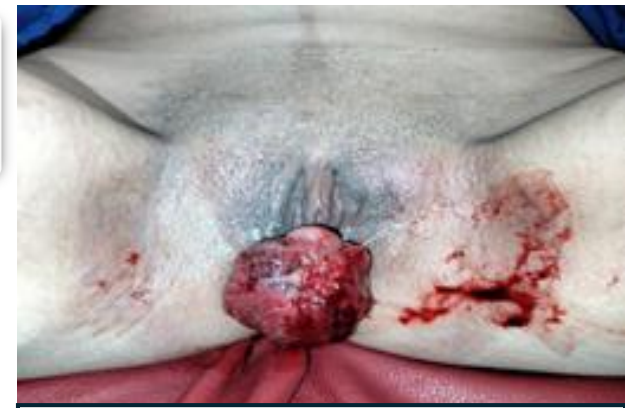

Figure 1: tumor cervical

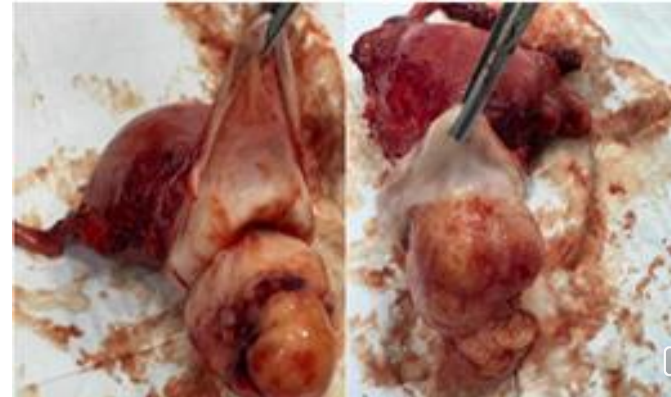


Figure 2: surgical specimen

# DISCUSSION

- Non-specific clinical presentation
- Diagnosis requires histopathology
- Multidisciplinary management is essential
- Prognosis depends on stage and histology

# CONCLUSION

- Rare and aggressive tumor
- Early diagnosis is crucial
- Requires specialized management
- Long- term follow-up is necessary

**THANK YOU FOR YOUR ATTENTION**

