

# Precision Colposcopy: Toward Individualized Risk Stratification of Cervical Lesions

Author: Tatsiana Pinchuk  
Belarusian State Medical University, Minsk, Belarus

**Background.** Differential diagnosis between LSIL and HSIL determines clinical management, including either observation or surgical treatment. Extended colposcopy enables visualization of lesions; however, its diagnostic criteria are not always definitive. This study evaluates the diagnostic value of extended colposcopy using the International Federation of Cervical Pathology and Colposcopy (IFCPC, 2011) classification for distinguishing LSIL from HSIL in young women with HPV-associated lesions.

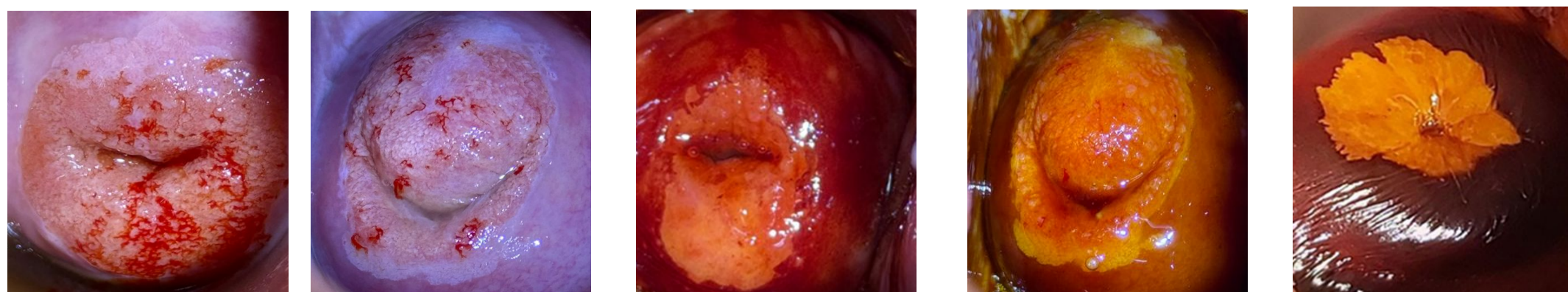
**Objectives.** To evaluate the value of extended colposcopy in the differential diagnosis of cervical intraepithelial lesions using IFCPC (2011) terminology.

**Methods.** A prospective cohort study was conducted at the Belarusian State Medical University between 2020 and 2025, including 191 women aged 18–35 years with HPV-associated, histologically confirmed cervical intraepithelial lesions. Patients were divided into LSIL (n = 111) and HSIL (n = 80) groups. Extended colposcopy was performed using a Leisegang 3ML LED colposcope, and findings were interpreted according to IFCPC criteria.

**Results.** Results are presented in Table 1.

Table 1 – Distribution of colposcopic findings in the study population

Parameter	Group 1, LSIL, 111 (n, %)	Group 2, HSIL, 80 (n, %)	Fisher's exact test, p
Transformation zone types 1	65 (58,56%)	37 (46,25%)	0,107
Transformation zone types 2	39 (35,14%)	25 (31,25%)	0,364
Transformation zone types 3	7 (6,31%)	18 (22,50%)	0,020
Rapid appearance of acetowhitening	22 (19,82%)	72 (90,00%)	< 0,001
Cuffed crypt (gland) openings	29 (26,13%)	34 (42,50%)	0,020
Transparent aceto-white epithelium	27 (24,32%)	1 (1,25%)	< 0,001
Milky aceto-white epithelium	66 (59,45%)	18 (22,50%)	< 0,001
Dense aceto-white epithelium	18 (16,22%)	61 (76,25%)	< 0,001
Inner border sign	1 (0,90%)	24 (30,00%)	< 0,001
Irregular border	22 (19,82%)	3 (3,75%)	< 0,001
Geographic border	88 (79,28%)	33 (41,25%)	< 0,001
Sharp border	1 (0,90%)	44 (55,00%)	< 0,001
Lesion size < 5 mm	12 (10,81%)	1 (1,25%)	0,009
Lesion size between 5 and 15 mm	80 (72,07%)	38 (47,50%)	< 0,001
Lesion size > 15 mm	19 (17,12%)	41 (51,25%)	< 0,001
Atypical vessels	37 (33,33%)	41 (51,25%)	0,017
Fine mosaic	21 (18,92%)	21 (26,25%)	0,288
Coarse mosaic	11 (9,91%)	13 (16,25%)	0,268
Fine punctation	13 (11,71%)	4 (5,00%)	0,128
Coarse punctuation	2 (1,80%)	17 (21,25%)	< 0,001
Ridge sign	1 (0,90%)	8 (10,00%)	0,004
Lugol's staining bright yellow	1 (0,90%)	53 (66,25%)	< 0,001



**Conclusion.** Assessment of colposcopic findings using IFCPC terminology is an effective tool for the early diagnosis and risk stratification of cervical intraepithelial lesions, supporting accurate clinical decision-making and improved quality of care. The sensitivity and specificity of extended colposcopy for HSIL were 75.87% and 69.05%, respectively. These findings highlight the value of extended colposcopy in the differential diagnosis of cervical lesions, as demonstrated by the high concordance between colposcopic and histological findings.